PROVIDING MALE SERVICES IN A TITLE X CLINIC

Deborah Bell, WHNP-BC, DNP
Kari Ehmann, WHNP-BC
Denver Metro Health Clinic
Denver Public Health

DISCLOSURES

Deborah Bell, NP, has no paid professional relationships to disclose.

Kari Ehmann, NP, has no paid professional relationship to disclose

OBJECTIVES

- Describe sexual history taking for male patients
- Review components of the male genital exam
- Outline options for client-centered counseling techniques
- Identify common disorders of the male reproductive system
- Discuss collection of labs
- Summarize diagnosis and treatment of common sexually transmitted infections

Title X Required Male Services

Sexual History

Contraceptive History

Reproductive Life Plan

Family/General/Med History

Medication History

Reason for visit

PERTINENT MEDICAL HISTORY

- Cardiovascular history
- Hypertension
- Neurologic/visual disturbances
- Metabolic history
- Neurologic history
- Hematologic history
- Genitourinary history
- Cancer history
- Vaccine history-Hepatitis A and B, HPV
- Drug and alcohol use

MEDICAL HISTORY

History

Medical History

Add | Pertinent Negative | Set Unanswered To No | Mark as Reviewed | Never

Anemia	Yes No	Heart Attack	Yes No	MPC	Yes No
Asthma	Yes No	Heart Disease	Yes No	NGU	Yes No
Bacterial vaginosis	Yes No	Hemophilia	Yes No	Numbness	Yes No
Bladder Disease	Yes No	Hepatitis B	Yes No	Ovarian Disorder	Yes No
Blood Clots	Yes No	Hepatitis C	Yes No	PID	Yes No
Breast disease	Yes No	Herpes	Yes No	Sickle cell anemia	Yes No
Cancer	Yes No	History of blood transfusion	Yes No	STD	Yes No
Chlamydia	Yes No	HIV/AIDS	Yes No	Stroke	Yes No
Convulsions	Yes No	HPV infection	Yes No	Syphilis	Yes No
Depression	Yes No	Hypercholesteremia	Yes No	Thyroid disease	Yes No
Diabetes mellitus	Yes No	Hyperlipidemia	Yes No	Transplant	Yes No
Emotional Problems	Yes No	Hypertension	Yes No	Trichomonas	Yes No
Epididymitis	Yes No	Inflammatory bowel disease	Yes No	Uterine Disease	Yes No
Epilepsy	Yes No	Jaundice	Yes No	Uterine Fibroids	Yes No
Gallbladder Problems	Yes No	Kidney disease	Yes No	UTI	Yes No
Genital warts	Yes No	Liver disease	Yes No	Vision problems	Yes No
Gonorrhea	Yes No	Lupus	Yes No	Yeast Infections	Yes No
Headaches	Yes No				

Other Medical History --- No other history on file ---

Surgical History

Add | Pertinent Negative | Mark as Reviewed | Never

No surgical history on file

MEDICAL HISTORY

Family History

View problems as: Checkboxes List Mark as Reviewed Never

Default View | Positives Only | Negatives Only

Relationship	Name	Status	No Known Problems	Add Problem	Alcohol abuse	Anemia	Birth defects	Cancer	Breast cancer	Colon cancer	Ovarian cancer	Uterine cancer	Cholecystitis	Diabetes	Drug abuse	Heart attack	Heart disease	Hemophilia	Hepatitis	Hyperlipidemia	Hypertension	Heart failure	Migraines	Miscarriages / Stil...	Premature CHD	Seizures	Sickle cell anemia	Stroke	Thrombosis
Mother																													
Father																													
Sister																													
Brother																													
Daughter																													
Son																													
MGM																													
MGF																													
PGM																													
PGF																													
Neg Hx																													

Add Family Member

Details:
Age of Onset:
Comments:

☐ Adopted ☐ Family history unknown

THE FIVE P'S FOR SEXUAL HISTORY TAKING

- Partners
- Practices
- Protection
- Past sexually transmitted infections
- Prevention of pregnancy

STD Rooming

? Actions ▾ Resize

Visit Info | Vital Signs | Allergies | History | Medications | Sex Hx | Risks & Drug Hx | Tobacco/Alcohol | BCM Probs & Life Plan | BCM Ed & Plan | Title X/Domestic Violence/Nutrition/Comm/Interpreter

PrEP | PAP/Mammo | Outside Meds | Goals | Period Details | SBIRT | MyChart Sign-up | MyChart Proxy | Verify Rx Benefits | Travel/Exposure

Sexual History

Sexual contact: Male — Never | < 4 months | 4-12 months | > 12 months

Sexual contact: Female — Never | < 4 months | 4-12 months | > 12 months

Sexual orientation: Heterosexual | Homosexual | Bisexual | Pansexual | Asexual | Undefined | Declined

Sex partners are most often: Female | Male | Both | Transwoman | Transman | Intersex | Other

Assigned sex at birth: Male | Female | Declined | Not Asked

Length of time since last sex: 1 | Days | Weeks | Months | Years

Current gender identity: Male | Female | Declined | Not Asked | Transgender MTF | Transgender FTM | Transgender Unspecified

Number of male partners in past 3 months? 1 | 2 | 3 | 4 | 5>

Number of new male partners in past 3 months? 1 | 2 | 3 | 4 | 5>

Number of female partners in past 3 months? 1 | 2 | 3 | 4 | 5>

Number of new female partners in past 3 months? 1 | 2 | 3 | 4 | 5>

Have your male partners had sex with other men? Yes | No | Unknown

Ever tested for HIV? Yes | No

Last test date:

Vaginal sex in past 3 months? Yes | No | Unknown

Given anal sex in past 3 months? Yes | No | Unknown

Received anal sex in past 3 months? Yes | No | Unknown

Given oral sex in past 3 months? Yes | No | Unknown

Received oral sex in past 3 months? Yes | No | Unknown

Ever had pain or other problems with sex? Yes | No

Last HIV test result? Positive | Negative | Unknown

Restore | Close F9 | Previous F7 | Next F8

Counseling Skills

- Respect
- Compassion
- Non-judgmental

Client Centered

- Motivational Interviewing (MI)

Open Ended

- Who, What, When, Where, How

THE PATIENT EXAM - TECHNIQUE

- Practice **Universal precautions**

- **Clean technique**
  - One hand clean, one hand contaminated
  - Two hands gloved, remove one glove before touching any clean surface area

- Wash hands before and after **every exam**

THE PATIENT EXAM - TECHNIQUE

- Communicate to patient
- Watch for signs of discomfort
- Touch a "non-genital" area of the body first
- Be professional and expeditious with exam
- Move exam light off of genital area as quickly as possible
- Examine painful areas last

COMPONENTS OF A MALE EXAM

- Oropharyngeal/external skin
- Pubic hair & thighs
- Inguinal lymph nodes
- Scrotum
- Penis
- Anus

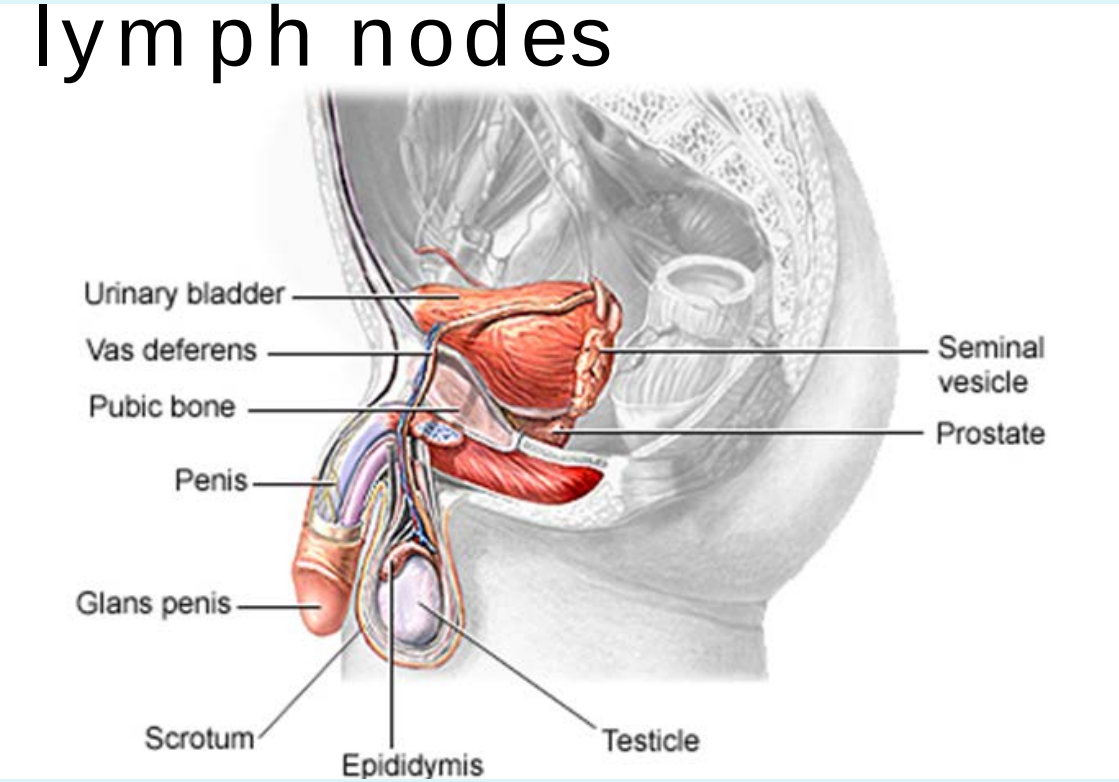

OROPHARYNGEAL EXAM

- Examination of the Inner Upper Lip

- Examination of the Inner Lower Lip

OROPHARYNGEAL EXAM

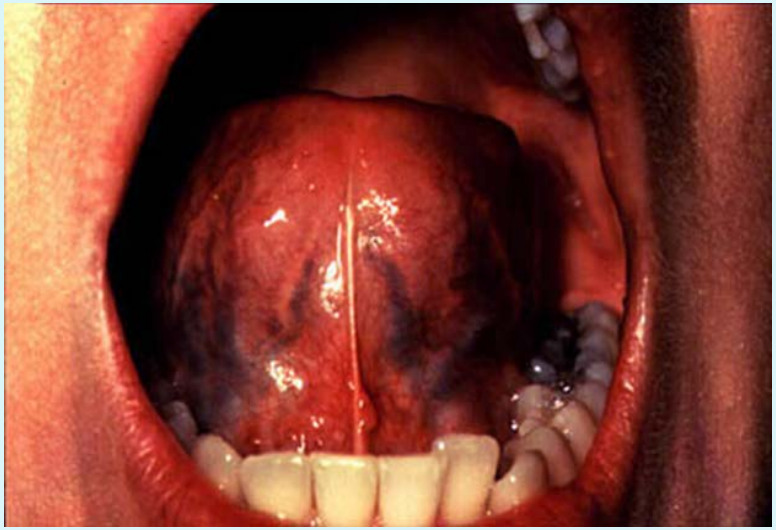

EXTERNAL SKIN SURFACE EXAM

- Palms and Soles of Fee
  - Secondary Syphilis
    Palmar Rash

- Other areas as indicated
  - Secondary syphilis:
    Papulosquamous rash

Source: http://www.cdc.gov/std/syphilis/stdfact-syphilis.htm

3 STEPS OF THE TESTICULAR EXAM

1. Testes
2. Epididymis
3. Spermatic Cord

Remember: Instruct patient on proper TSE technique

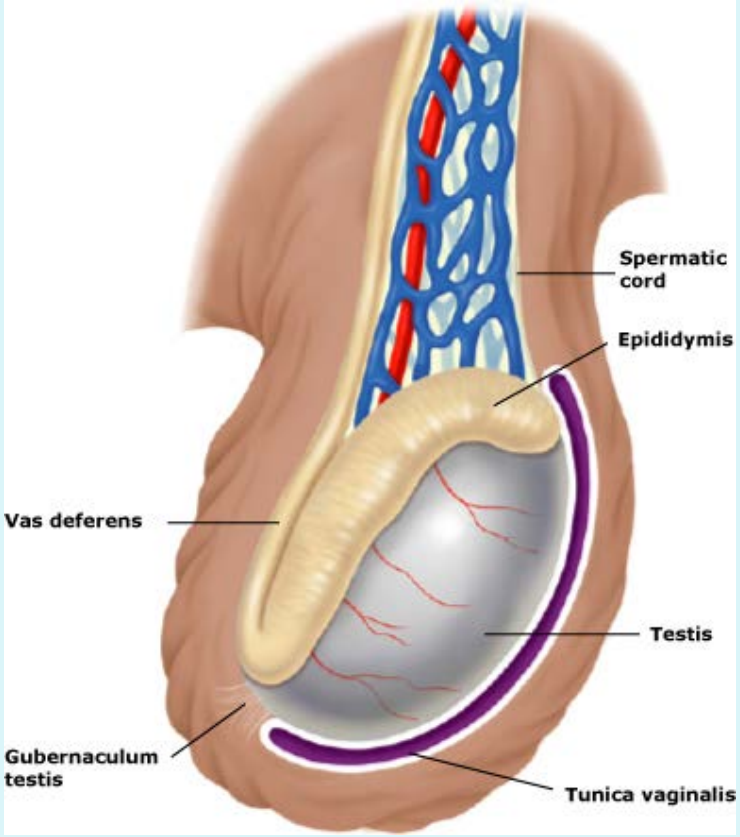

Normal Testicular Anatomy

EXAMINATION OF THE PENIS

- Normal urethral meatus
- Urethral Exam
  - Milk penis to inspect for urethral discharge
  - Visual inspection for HPV

PROSTATE EXAM

- Assume the position!
  - Lubricate index finger
  - Ask patient to bear down for visual inspection
  - Locate anus visually to confirm finger placement
  - Ask patient to tighten anus and then relax
    - With relaxation, insert finger palm down
- Prostate Palpation
  - Identify sulcus and 2 lobes
  - Should NOT feel hard or spongy
  - Remove finger while rotating 360ºassessing for tone, polyps, hemorrhoids
  - Assess for blood

NORMAL VARIATIONS OF THE MALE EXAM

- **Fordyce Spots** - visible sebaceous glands and occur along the shaft of the penis

- **Tyson's Glands** - ectopic sebaceous glands that appear in pairs as openings on either side of the

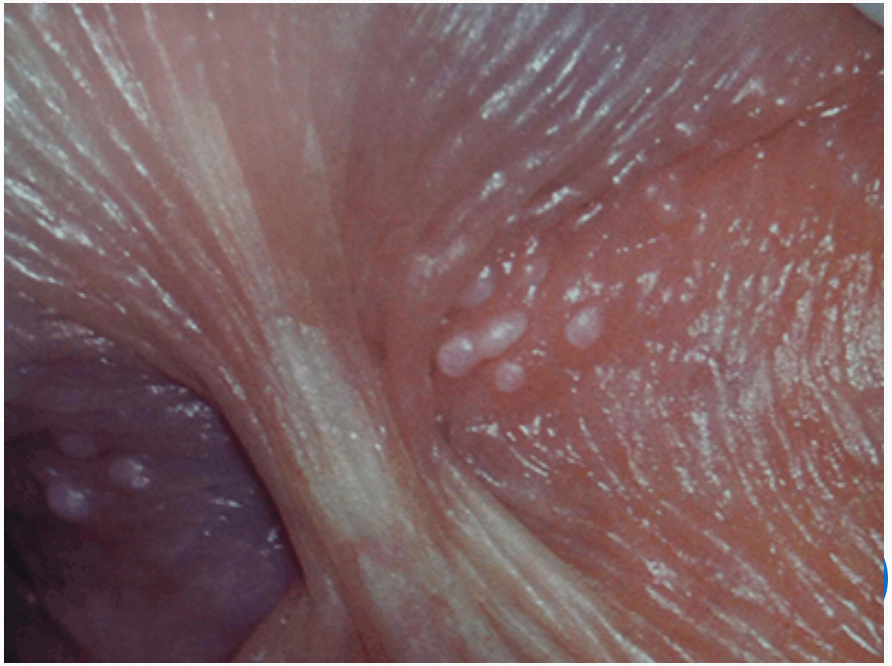

Source: http://www.racgp.org.au/afp/2013/may/penile-

NORMAL FINDING

SMEGMA

COMMON DISORDERS: PENIS AND URETHRA

- **Hypospadius-** urethal opening located on *ventral meatus*

- **Epispadius-** urethral opening located on *dorsal meatus*

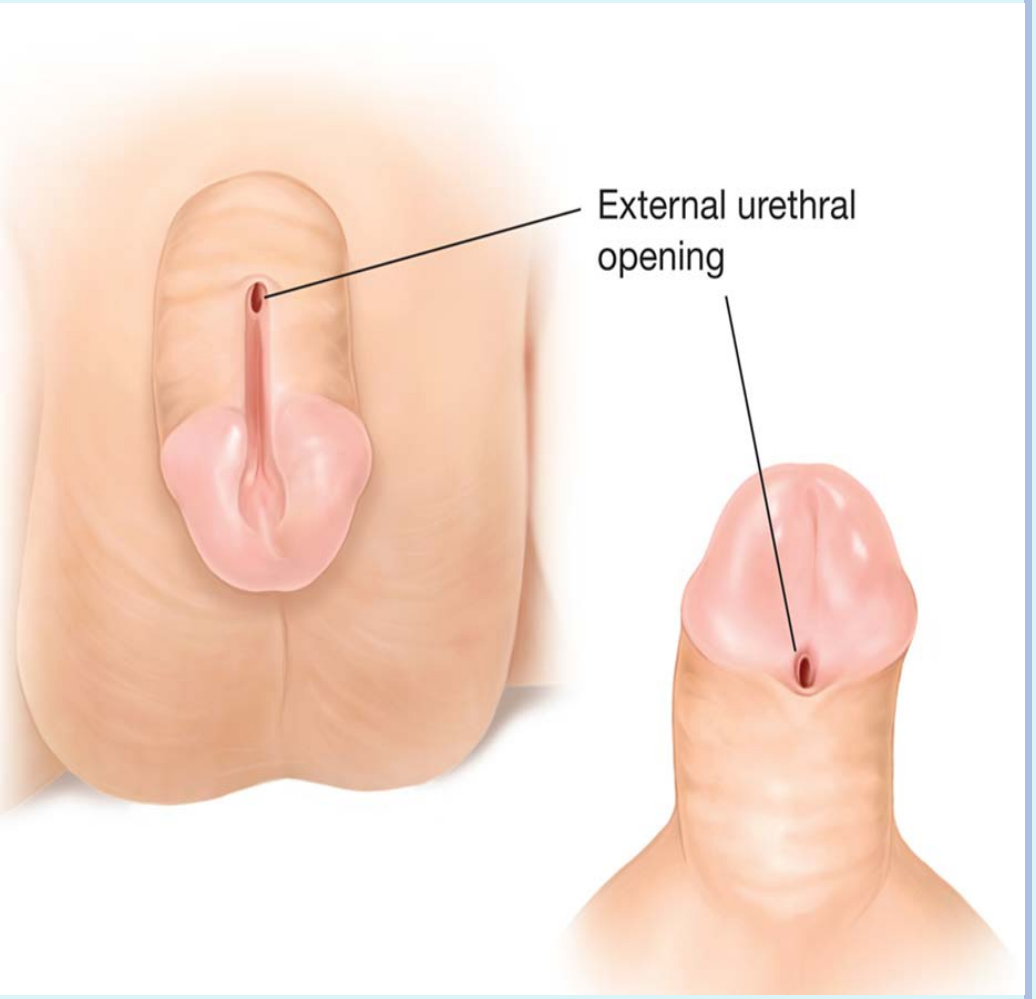

COMMON DISORDERS: PENIS AND URETHRA

Balanoposthitis
inflammation of the glans penis and foreskin

Balanitis
inflammation of the glans penis

Source: www.primehealthchannel.com/balanitis-pictures-causes-symptoms-and-treatment.html

COMMON DISORDERS: PENIS AND URETHRA

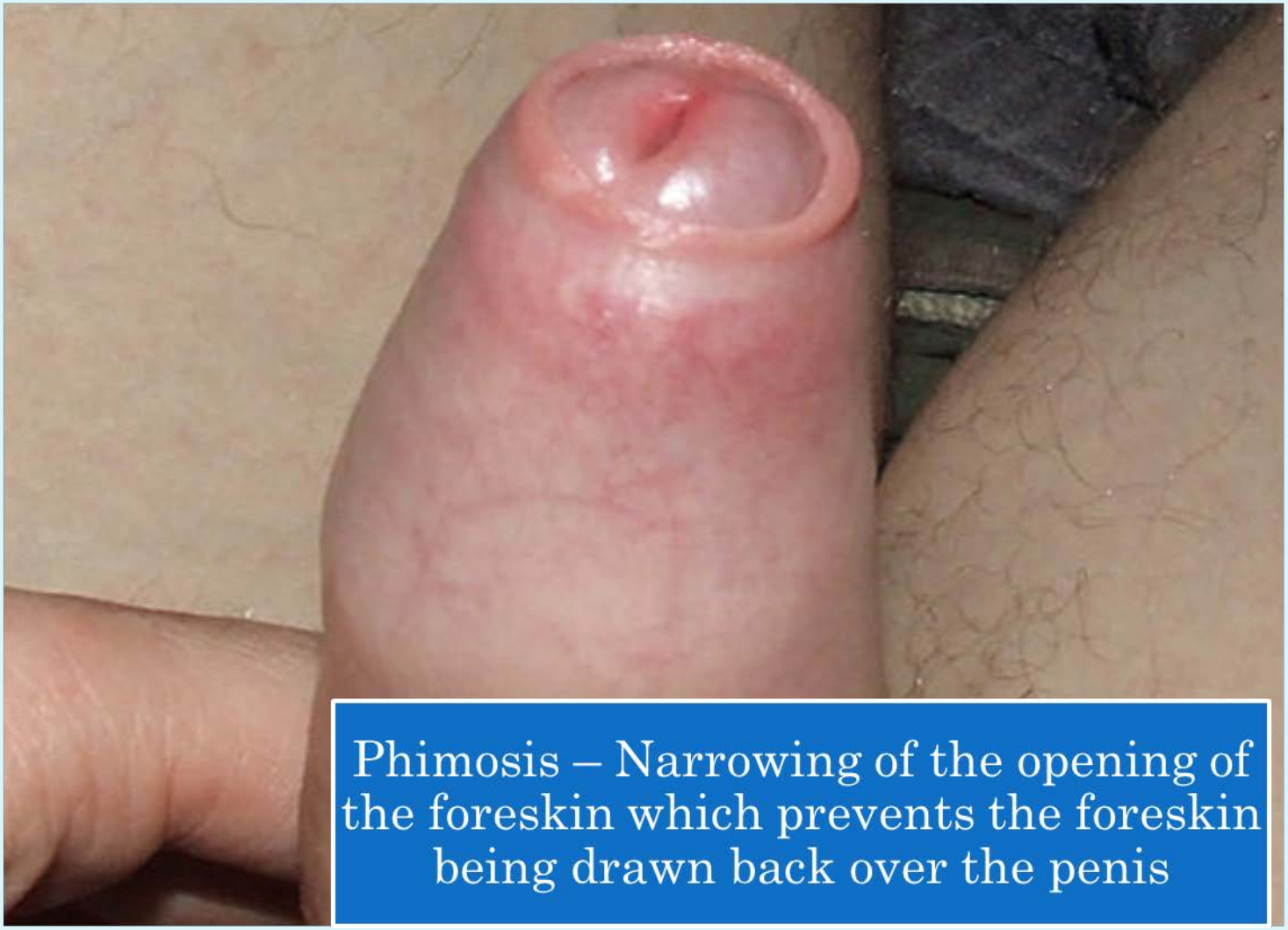

COMMON DISORDERS: SCROTUM AND GROIN

- Hydrocele
- Varicocele

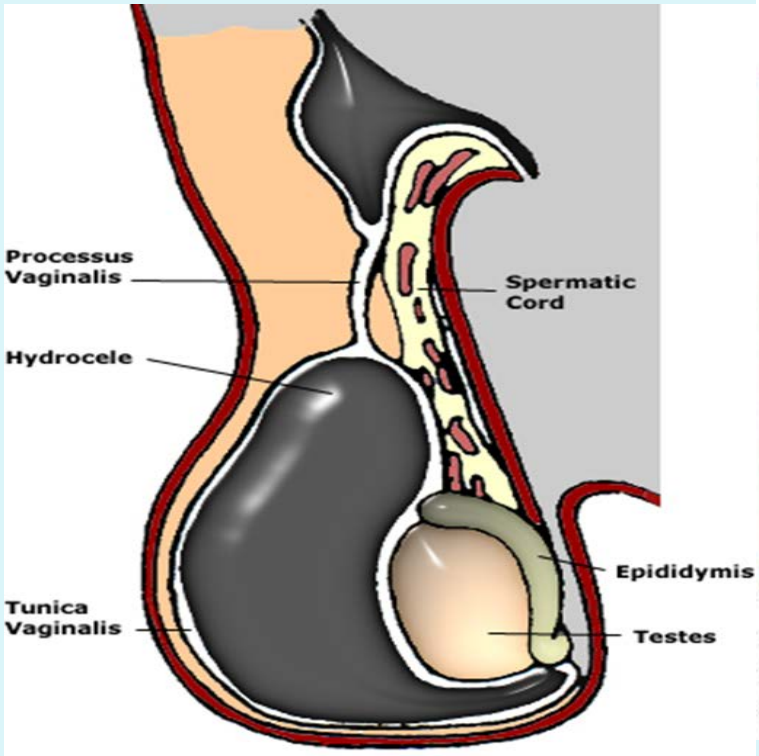

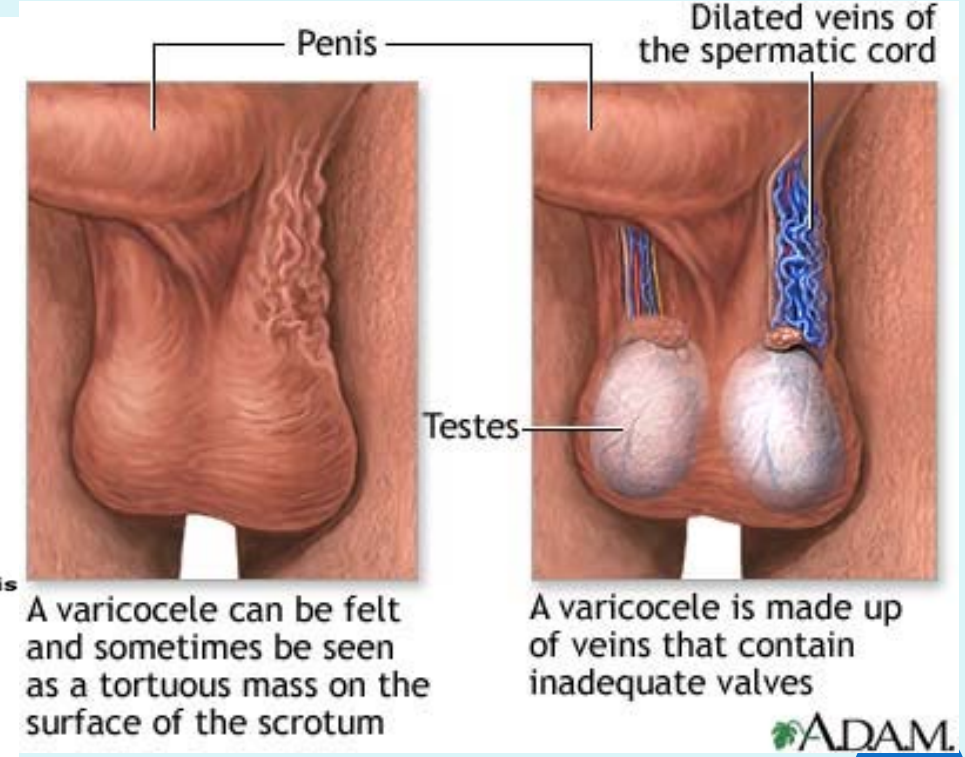

COMMON DISORDERS: SCROTUM AND GROIN

- Spermatocele
- Epididymitis

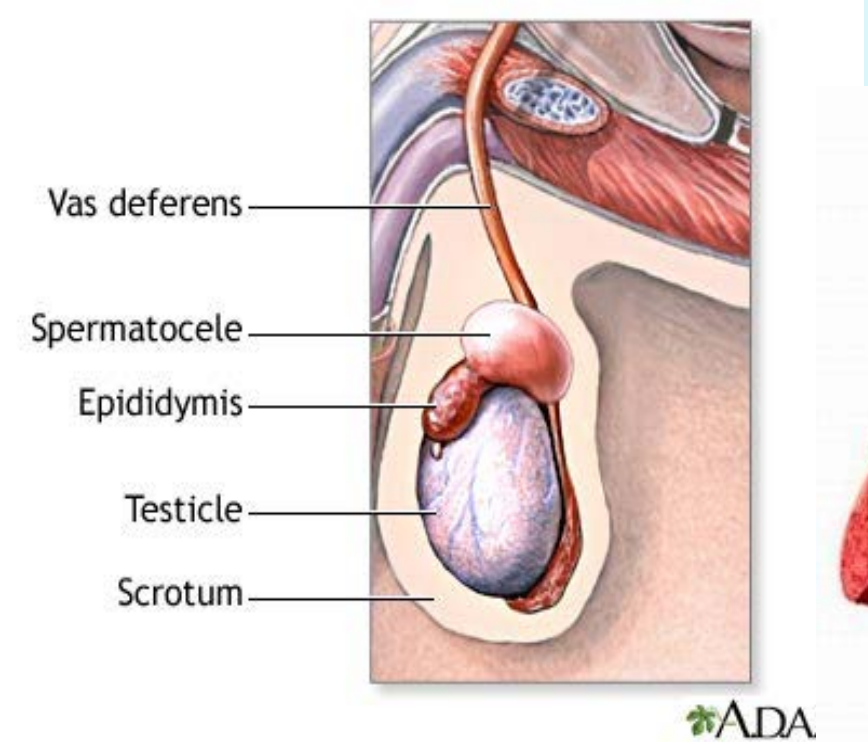

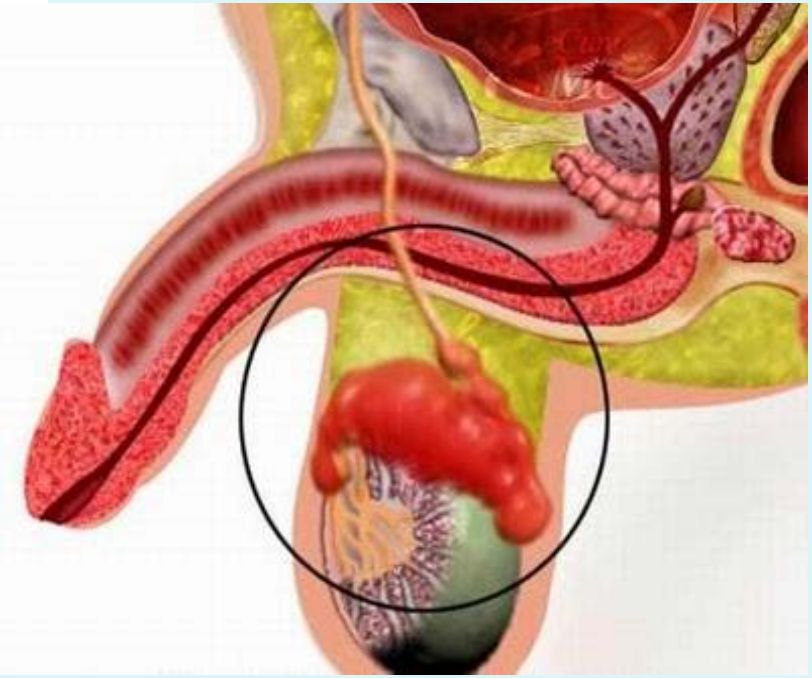

DISORDERS OF THE TESTICLES

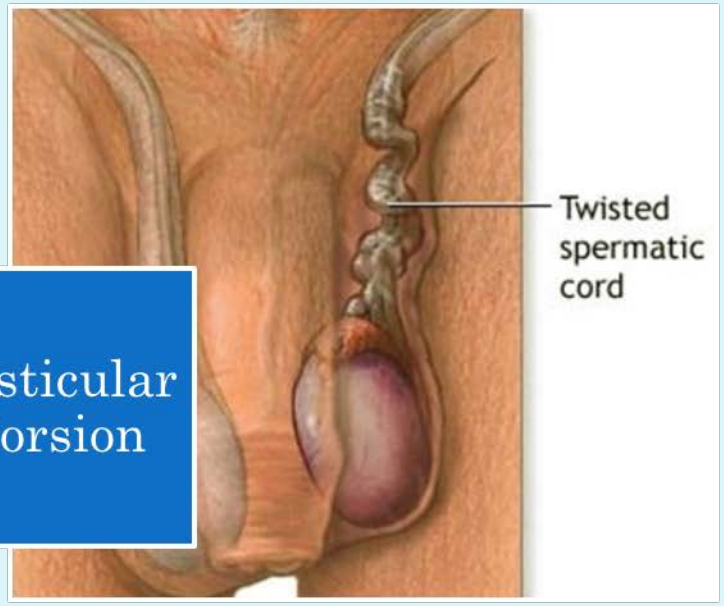

Testicular Torsion

Scrotal Wall Abscess

COMMON DISORDERS: DERMATOLOGICAL

Fixed drug eruption

Tinea cruris

Tinea cruris

COMMON DERMATOLOGIC FINDINGS

- Scrotal Epidermoid Cysts

COMMON DERMATOLOGIC FINDINGS

Pearly Penile Papules	Molluscum contagiosum

COMMON DISORDERS

Inguinal hernia

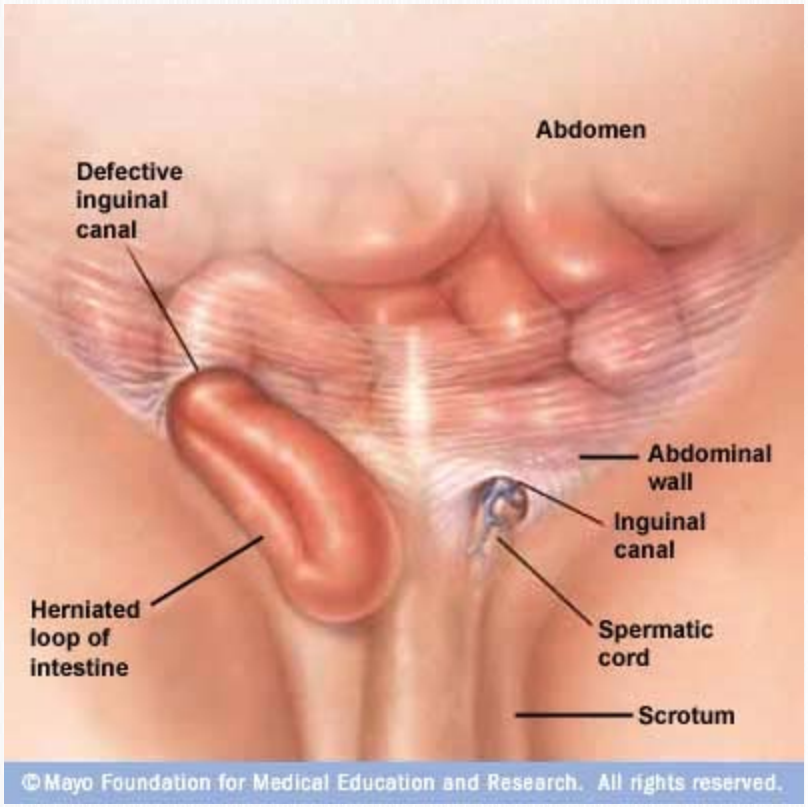

INGUINAL HERNIA EXAM

COMMON DISORDERS: PROSTATITIS

Background

- Bacterial
  - Gram negative coliform
  - Gonorrhea/Chlamydia

Symptoms

- Decreased urine flow
- Perineal pain
- Dysuria
- Fever

Diagnosis

- Rectal Exam
  - Warm, swollen, firm and irregular

COMMON DISORDERS: PROSTATITIS

Lab	• Urethral gram stain • CT/GC Aptima • Urinalysis with Micro
Treatment	• Levaquin 500mg po daily x 7 days • F/U with PCP to complete tx

SEXUALLY TRANSMITTED GASTROINTESTINAL SYNDROMES

Proctitis

- Inflammation of the rectum with anorectal pain, rectal discharge, and tenesmus
- Primarily with receptive anal sex

Proctocolitis

- Symptoms of proctitis with abdominal cramping or diarrhea occurring > 15 cm into sigmoid colon
- Occurs with receptive anal and anal-oral sex

Enteritis

- Diarrhea and abdominal cramping but no signs of proctitis and proctocolitis
- Occurs with oral-anal contact

DIAGNOSIS OF PROCTITIS

Anoscopic exam of rectum with collected gram stain, HSV culture, and RPR depending on findings.

TREATMENT OF PROCTITIS

Recommended Regimens
Ceftriaxone 250 mg IM, single dose
PLUS
Doxycycline 100 mg orally twice daily for 7 days

If lesions suspicious for HSV are noted on exam, treat for HSV. If LGV suspected, treat with doxycycline 100 mg twice daily for 3 weeks.

Source: CDC 2015 STD Treatment Guidelines

ROUTINE COLLECTION OF MALE LABS

Urethral Gram Stain	• Signs or symptoms of urethritis
CT/GC Aptima	• Pharyngeal (MSM) • Rectal (MSM)
Urine CT/GC Aptima	• All male patients
HIV Rapid Test	• Annually • Every 3 months in MSM population
Syphilis Serology	• If contact to syphilis • Sign/symptoms of syphilis • Every 3 months in MSM population

ADDITIONAL LABS IF INDICATED

ADDITIONAL TESTING IF INDICATED – RAPID HCV

- Injected or snorted drugs, even one time
- Were born between 1945-1965
- Received any blood products before 1992 or outside the U.S.
- Had sexual contact with someone with Hep C
- Received a tattoo outside of a licensed setting



DIAGNOSIS OF NGU

Diagnosed with the presence of two or more WBCs in the absence of gram-negative intracellular diplococci

In the absence of a gram stain, diagnosis is based on symptoms

Source: CDC 2015 STD Treatment Guidelines

TREATMENT OF NGU

Recommended Regimens
Azithromycin 1gm orally, single dose
OR
Doxycycline 100 mg po bid x 7 days

Source: CDC 2015 STD Treatment Guidelines

DIAGNOSIS AND TREATMENT: PERSISTENT NGU

Original treatment included	Risk	Recurrent NGU treatment
Doxycycline	Vaginal sex (Possible trich exposure)	Azithromycin Metronidazole
Doxycycline	No vaginal sex (No possible trich exposure)	Moxifloxacin
Azithromycin	Vaginal sex (Possible trich exposure)	Metronidazole as first line tx for MSW If pt was tx with Metronidazole and continues to have symptoms, tx with Moxifloxacin
Azithromycin	No vaginal sex (No possible trich exposure)	Moxifloxacin

Source: CDC 2015 STD Treatment Guidelines

DIAGNOSIS OF CHLAMYDIA

Culture	NAAT	DNA Probe
Sensitivity: 50-90% Specificity: 99.9%	Sensitivity: >90%* Specificity: 99.7%	Sensitivity: 40-65% Specificity: 99%
	Preferred	

*For urethral and urine testing

Source: CDC

TREATMENT OF CHLAMYDIA

Recommended Regimens
Azithromycin 1gm orally, single dose
OR
Doxycycline 100 mg po bid x 7 days

Source: CDC 2015 STD Treatment Guidelines

DIAGNOSIS OF GONORRHEA

Culture	NAAT	Gram Stain	DNA Probe
Sensitivity: 90% **Specificity:** 99%	**Sensitivity:** 85-90% **Specificity:** >98%	**Sensitivity:** 95% **Specificity:** 99%	**Sensitivity:** 35-45% **Specificity:** 99%
	Preferred	*Urethral Gram stain Very good test for symptomatic males. Not recommended for rectal or pharyngeal sites.*	

Source: CDC

GONORRHEA

Source: UCHSC STD Library;
Reproduced with permission from: Rubin E, Farber JL. Pathology, 3rd ed, Lippincott Williams & Wilkins, Philadelphia 1999. Copyright © 1999 Lippincott Williams & Wilkins.

TREATMENT OF GONORRHEA

Recommended Regimens*
Ceftriaxone 250 mg IM, single dose
PLUS
Azithromycin 1gm orally, single dose

If Ceftriaxone is not available:
Cefixime 400 mg orally, single dose

*For other alternative regimens see 2015 CDC STD Treatment Guidelines

Source: CDC 2015 STD Treatment Guidelines

GONORRHEA: MANAGEMENT OF SEX PARTNERS

Evaluate all sex partners

Presumptively treat **all** partners if last sexual contact within 60 days of onset of symptoms/diagnosis in index patient. Use EPT!

Presumptively treat **most recent** partner even if last sexual contact > 60 days

Avoid sex until therapy completed and patient/partner are asymptomatic

Source: CDC 2015 STD Treatment Guidelines

EPIDIDYMITIS

Source: Health Awareness Connection, http://www.healthac.org/images.html

DIAGNOSIS OF EPIDIDYMITIS

Diagnosed based on clinical findings-unilateral testicular pain, tenderness, palpable swelling, usually noted at the tail of the epididymis. The symptoms can involve the whole epididymis and the testicle.

Gram stain of 2 or more WBCs is supportive of the diagnosis.

TREATMENT OF EPIDIDYMITIS

Recommended Regimens*
Ceftriaxone 250 mg IM, single dose
PLUS
Doxycycline 100 mg orally twice daily for 10 days

Oflaxacin 300 mg twice a day for 10 days if likely enteric bacteria-insertive anal sex

*For other alternative regimens see 2015 CDC STD Treatment Guidelines

Source: CDC 2015 STD Treatment Guidelines

FOLLOW-UP AND PARTNER TREATMENT

- No sexual activity for 10 days
- Return to clinic within 72 hours if symptoms do not improve
- Treatment of all partners in the past 60 days or most recent partner

CASE STUDY

- A man, 34 years of age, presented with a 4 day history of painless ulcerative lesions on his penis. He was human immunodeficiency virus (HIV) negative and had previously been well. He had received unprotected oral sex from a male partner about 3 weeks before the onset of the ulcers. There was no urethral discharge or dysuria.
- Examination revealed discrete, nontender, superficial ulcers on the penis; 1–2 cm in diameter with rolled, indurated borders (*Figure 1a, b*). Bilateral inguinal lymphadenopathy was present. The remainder of the physical examination was unremarkable. A serologic test for syphilis showed a negative rapid plasma reagin test result.

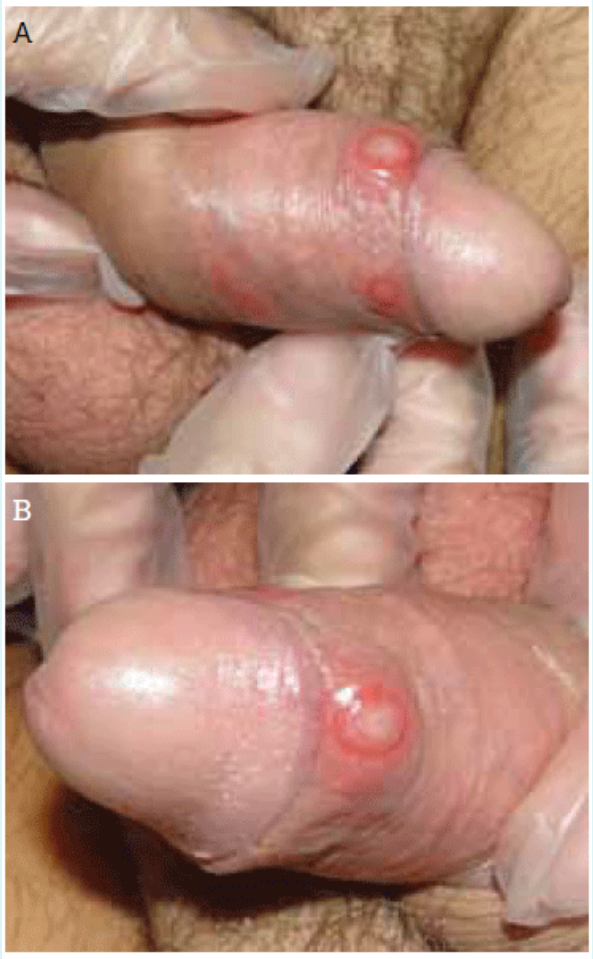

Source: http://www.racgp.org.au/afp/2012/september/multiple-penile-lesions/

CASE STUDY QUESTIONS

Question 1
Based on the history and physical examination, what is the most likely diagnosis?

Question 2
What is the differential diagnosis?

Question 3
Why does the patient have a negative rapid plasma reagin test result and what other tests can be used to aid the diagnosis?

Question 4
What are the treatment options for early syphilis?

DIAGNOSIS OF SYPHILIS

Non-treponemal

- Detects non-specific antibodies caused by damage to cell membrane
- Reflects activity of disease
- Screening or confirmatory
- RPR (VDRL)

Treponemal

- Detects specific antibodies against *T. pallidum*
- Remains positive after 1st infection
- Screening or confirmatory
- FTA-ABS, TPPA, EIA

SENSITIVITY OF SEROLOGICAL TESTS IN UNTREATED SYPHILIS

	Stage of Disease (Percent Positive (Range))			
Test	Primary	Secondary	Latent	Tertiary
RPR	78 (74-87)	100	95 (88-100)	71 (37-94)
FTA-ABS*	84 (70-100)	100	100	96
Treponemal Agglutination*	76 (69-90)	100	97 (97-100)	94
EIA/CIA	90 (82-93)	100	100	Not available

FALSE-POSITIVE RPR

General Population
1-2%

Causes of False Positives on RPR				
IV drug use (10%)	Pregnancy	Major febrile illnesses	Autoimmune disorders	Aging

PRIMARY SYPHILIS: CHANCRE

Source: DMHC, UCHSC STD Library

PRIMARY SYPHILIS: ANAL CHANCRE

Source: UCHSC STD Library

SECONDARY SYPHILIS

Source: Source: CDC/NCHSTP/Division of STD Prevention, STD Clinical Slides

SECONDARY SYPHILIS

Source: DMHC

SECONDARY SYPHILIS: PAPULOSQUAMOUS RASH

Source: DMHC

SECONDARY SYPHILIS: PAPULOSQUAMOUS RASH

Source: UCHSC STD Library

SECONDARY SYPHILIS: ANNULAR RASH

Source: CDC, DMHC

SECONDARY SYPHILIS: MUCOUS PATCHES

Source: DMHC

SECONDARY SYPHILIS: CONDYLOMA LATA

Source: CDC

SECONDARY SYPHILIS: PATCHY ALOPECIA

Source: CDC; UpToDate

ADDITIONAL CONSIDERATIONS

http://www.cdc.gov/std/syphilis/clinicaladvisoryos2015.htm

CDC - Clinical Advisory: Oc...

CDC Centers for Disease Control and Prevention
CDC 24/7: Saving Lives, Protecting People™

SEARCH

CDC A-Z INDEX

Sexually Transmitted Diseases (STDs)

- Syphilis
- Facts & Brochures +
- Statistics +
- Treatment and Care –
  - Clinical Advisory: Ocular Syphilis in the United States
- Other Resources
- Archive +

STDs Home Page

- Bacterial Vaginosis (BV)
- Chlamydia
- Gonorrhea
- Genital Herpes
- Hepatitis
- HIV/AIDS & STDs
- Human Papillomavirus (HPV)
- Pelvic Inflammatory Disease (PID)
- STDs & Infertility
- STDs & Pregnancy
- Syphilis
- Trichomoniasis
- Other STDs

See Also

Sexually Transmitted Diseases (STDs) > Syphilis > Treatment and Care

Clinical Advisory: Ocular Syphilis in the United States

Updated March 24, 2016

Between December 2014 and March 2015, 12 cases of ocular syphilis were reported from two major cities, San Francisco and Seattle. Subsequent case finding indicated more than 200 cases reported over the past 2 years from 20 states. The majority of cases have been among HIV-infected MSM; a few cases have occurred among HIV-uninfected persons including heterosexual men and women. Several of the cases have resulted in significant sequelae including blindness.

Ocular syphilis can involve almost any eye structure, but posterior uveitis and panuveitis are the most common. Additional manifestations may include anterior uveitis, optic neuropathy, retinal vasculitis and interstitial keratitis. Ocular syphilis may lead to decreased visual acuity including permanent blindness. Ocular syphilis can be associated with neurosyphilis. Both ocular syphilis and neurosyphilis can occur at any stage of syphilis, including primary and secondary syphilis. While previous research supports evidence of neuropathogenic strains of syphilis, it remains unknown if some *Treponema pallidum* strains have a greater likelihood of causing ocular infections.

- **Clinicians should be aware of ocular syphilis and screen for visual complaints in any patient at risk for syphilis** (MSM, HIV-infected persons, others with risk factors and persons with multiple or anonymous partners).
- **All patients with syphilis should receive an HIV test if status is unknown or previously HIV-negative**
- **Patients with positive syphilis serology and early syphilis without ocular symptoms should receive a careful neurological exam including all cranial nerves.**
- **Patients with syphilis and ocular complaints should receive immediate ophthalmologic evaluation.**
- **A lumbar puncture with cerebrospinal fluid (CSF) examination should be performed in patients with syphilis and ocular complaints.**
- **Ocular syphilis should be managed according to treatment recommendations for neurosyphilis** (Aqueous crystalline penicillin G IV or Procaine penicillin IM with Probenecid for 10-14 days)
- **Cases of ocular syphilis should be reported to your state or local health department within 24 hours of diagnosis. Ocular syphilis cases diagnosed since December 1, 2014, should be reported to your local or state health department.** The case definition for an ocular syphilis case is as follows: a person with clinical symptoms or signs consistent with ocular disease (i.e. uveitis, panuveitis, diminished visual acuity, blindness, optic neuropathy, interstitial keratitis, anterior uveitis, and retinal vasculitis) with syphilis of any stage.

Pre-antibiotic clinical samples (whole blood, primary lesions and moist secondary lesions, CSF or ocular fluid) should be saved and stored at -80°C immediately upon collection for molecular typing.

If you are a healthcare provider and need advice from CDC regarding the clinical management of ocular syphilis, contact Dr. Kimberly Workowski at 404-639-1898 or kgw2@cdc.gov. If you are planning on collecting clinical specimens for molecular typing and need assistance with the collection procedure or shipment of samples, please contact Dr. Allan Pillay at 404-639-2140 or ajp7@cdc.gov.

9:00 AM
5/12/2016

TREATMENT OF SYPHILIS

Recommended Regimens – *Primary, Secondary, Early Latent*
Benzathine Penicillin G, 2.4 million units IM x 1

Recommended Regimens – *Late or Unknown Latent*
Benzathine Penicillin G, 2.4 million units IM at one week intervals x 3 doses

*Benzathine Penicillin G = Long-Acting Bicillin (LAB)

Source: CDC 2015 STD Treatment Guidelines

SYPHILIS TREATMENT FOLLOW-UP

Early (Primary and Secondary)	Latent (Early, Late, or Unknown)
• If lesions present, clinical exam in 1 week • Clinically evaluate and repeat RPR at 6 and 12 months • Suggest HIV test with repeat HIV test at 6 months • If known HIV+, repeat RPR at 3, 6, 9, 12 and 24 months	• Repeat RPR at 6, 12 and 24 months • If known HIV+, repeat RPR at 6, 12, 18 and 24 months

FOLLOWING RPR TITERS

January 2013

Test & Treat:
RPR = 1:32

July 2013

RPR: 1:8
(4-fold decrease)

RPR: 1:128
(4-fold increase)

January 2014

Early disease:
Seronegative within 1 year

Latent disease: Low titer may persist for life

TREATMENT OF SYPHILIS CONTACTS

Treat presumptively if:

- Exposure to primary, secondary, early latent $\leq$ 90 days
- Exposure to primary, secondary, early latent > 90 days (if no serology is available)
- Exposure to unknown latent syphilis

DIAGNOSIS OF LOW-RISK HPV

Genital Warts

- Diagnosed by visual inspection
- Usually types 6 and 11

Source: Cincinnati STD/HIV Prevention Training Center

GENITAL WARTS: MALES

Source: Cincinnati STD/HIV Prevention Training Center

Genital Warts: Provider-Administered Treatments

Cryotherapy:

Liquid nitrogen or cryoprobe

Repeat every 1-2 weeks as needed

Trichloroacetic acid (TCA) 80-90%:

Repeat every 1-2 weeks as needed

Surgical removal: Scissor excision, shave excision, curettage, or electrosurgery

HSV DIAGNOSIS

Virus culture

- Gold standard
- Highly specific (>99%)
- Sensitivity declines as lesions heal
  - Vesicles = 90%
  - Ulcers = 70%
  - Crusted lesions = 30%
- Positive more often in primary infections (80-90%) than with recurrences (30%)

PCR

- Highly specific (>99%)
- Highly sensitive (about 95%)
- FDA-cleared
- Costly
- Test of choice for CSF

TYPE-SPECIFIC SEROLOGIC TESTING

- Sensitivities for HSV-2 antibody vary from 80% to 98%; false-negative results may occur, especially at early stages of infection
- Specificities are ≥ 96%, but false positives can occur
- Perform serologic testing 8-12 weeks after outbreak or exposure.

Source: Wald & Ashley-Morrow, CID 2002;35S:S173-S182

HERPES

Source: DHMC

HERPES

Primary outbreak

- Extensive
- Bilateral

Source: DMHC

HSV TREATMENT

Recommended Regimen – FIRST EPISODE[1]
Acyclovir 400mg TID x 7-10 days
Famciclovir 250mg TID x 7-10 days
Valacyclovir 1g BID x 7-10 days
Recommended Regimen – EPISODIC[2]
Acyclovir 800mg TID x 2 days
Famciclovir 1000mg BID x 1 day
Valcyclovir 500mg BID x 3 days
Valcyclovir 1g once a day x 5 days

[1] May extend if symptoms are severe.

[2] See CDC Treatment Guidelines for alternate regimens; Initiate episodic treatment within 1 day of lesion onset

Source: CDC 2015 STD Treatment Guidelines

HSV TREATMENT

Recommended Regimen – SUPPRESSION
Acyclovir 400mg BID
Famciclovir 250mg BID
Valacyclovir 500mg or 1g Daily

Source: CDC 2015 STD Treatment Guidelines

ADDITIONAL MALE SERVICES

- **Triage/Express Visits** to enhance efficiency
- **EPT** – Expedited partner therapy
- "**Online Services**" – ability to obtain test results online
- HIV/HCV **Linkage to Care**

ADDITIONAL RESOURCES

- http://www.cdc.gov/reproductivehealth/UnintendedPregnancy/QFP.htm
- https://www.cdc.gov/std/tg2015/default.htm
- http://www.maletrainingcenter.org/
- http://www.maletrainingcenter.org/wp-content/uploads/2014/09/MTC_White_Paper_2014_V2.pdf

CONTACT INFORMATION

- Deborah Bell – deborah.bell@dhha.org

- Kari Ehmann – kari.olson@dhha.org

DMHC

- www.denverstdclinic.org
- 303 602-3540

DPH

- www.denverhealth.org/public-health-and-wellness/public-health
- 303 602-3700

PTC

- www.denverptc.org
- 303 602-3608

THANK YOU

Denver Prevention Training Center	Denver Metro Health Clinic
• Alison Finkenbinder, MSN, WHCNP-BC	• Angela Montgomery, MS,RN • DMHC STAFF